

PHOTOBIO-MODULATION AS A TREATMENT IN DRY AMD



Doctors and patients have found this new mode of therapy beneficial.

BY HAKAN KAYMAK, MD; AND HARTMUT SCHWAHN, PHD

The development of innovative treatments for debilitating diseases such as age-related macular degeneration (AMD) is crucial to advance patient care and to reduce burdens on patients, caregivers, and physicians. The dry, or nonexudative, form of AMD affects approximately 85% to 90% of individuals with AMD, and, until now, there have been no approved treatments for this condition aside from nutritional supplementation.

The Valeda Light Delivery System (LumiThera) was designed as a safe, multiwavelength platform for photobiomodulation (PBM). The device received the CE Mark in the European Union, where its indicated uses include treatment of ocular damage and disease using PBM, including inhibition of inflammatory mediators, edema, or drusen deposition; improvement of wound healing following ocular trauma or surgery; and increase in visual acuity and contrast sensitivity in patients with degenerative diseases such as dry AMD.

The underlying mitochondrial mechanisms of PBM therapy and recent clinical studies demonstrating positive improvements in patients¹⁻⁵ have increased interest in PBM as a treatment approach in dry AMD.

In our specialty clinic for vitreous, retina, and macula therapy, we see 20 to 40 patients with macular degeneration, particularly AMD, each day. For about a year now, we have

offered PBM treatment with Valeda to patients as an alternative or supportive treatment option for dry AMD.

INTRO TO PHOTOBIO-MODULATION

PBM is a light-based technology that stimulates bioenergetic output in targeted tissues. Selected wavelengths of light in the far red to near infrared spectrum (500–1,000 nm) modulate biologic function through direct and indirect cellular effects on mitochondrial respiratory chain components. The retina is one of the most energy-demanding tissues in the body. PBM activation of photoacceptors in the mitochondria improves generation of adenosine triphosphate (ATP), modulates the production of intracellular signaling molecules such as reactive-oxygen species (ROS) and nitric oxide (NO), and triggers secondary effects that produce sustained changes in cell function and viability.

These changes in cellular outcomes lead to therapeutic benefits at the clinical level. The treatment parameters of PBM are crucial, as PBM displays a biphasic dose-response output. Selection of wavelengths and the dose, timing, and delivery of PBM treatment must be appropriate to elicit these beneficial cellular effects.

Preclinical evidence supports the use of PBM as an effective treatment in retinal cell injury and multiple animal models of ocular disease and disorders.⁶⁻⁸ Small pilot studies have shown promising effects for PBM in dry AMD and other ocular indications.^{1-3,9-11} In recently published results, a double-masked, randomized, sham-controlled study in patients with dry AMD (LIGHTSITE I) demonstrated improvements in clinical measures (visual acuity and contrast sensitivity) and reduction in anatomic

AT A GLANCE

- ▶ The Valeda Light Delivery System is a light-based approach to treatment with a CE Mark in the European Union for multiple ocular indications, including dry AMD.
- ▶ Photobiomodulation (PBM), as performed with the Valeda, acts at the mitochondrial level by improving cellular output and reestablishing metabolic function.
- ▶ Patients with dry AMD treated with PBM have shown improvements in clinical, anatomic, and quality-of-life assessments.

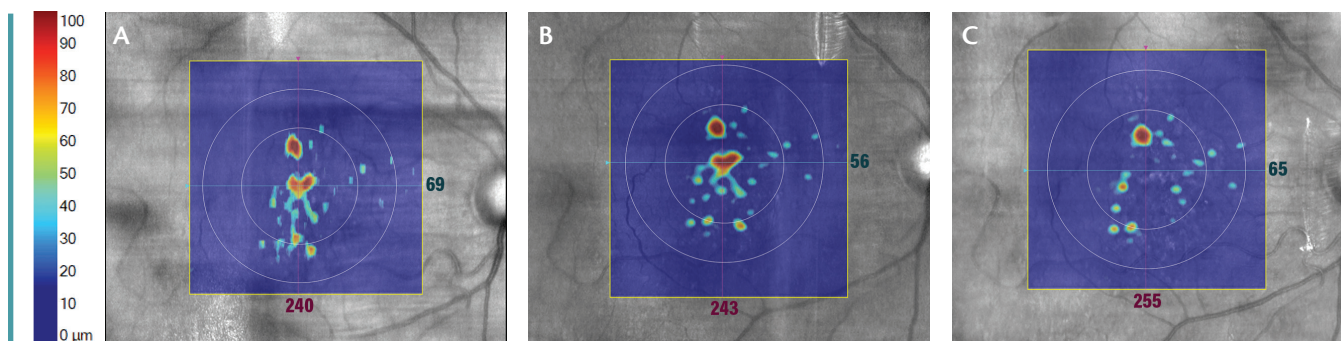


Figure 1. Color-coded analysis of retinal pigment epithelium (RPE) detachment from choroid as a measure of drusen status in OCT of the right eye at 12 months before the beginning of PBM treatment (A), at the beginning of PBM (B), and 7 months after treatment (C).

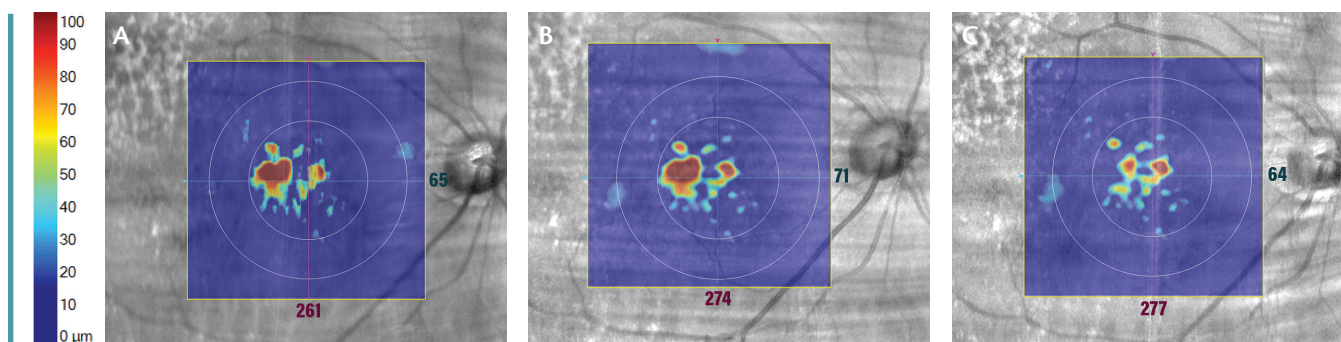


Figure 2. Color-coded analysis of RPE detachment from choroid as a measure of drusen status in OCT of the right eye at 6 months before the beginning of PBM treatment (A), at the beginning of PBM (B), and 2 months after beginning of treatment (C).

measures (drusen volume and thickness), along with improvement in quality-of-life endpoints.³

These findings support further study of the use of PBM as a treatment option for dry AMD patients. In our own clinic we have observed the beneficial effects of PBM treatment, as illustrated anecdotally by the following case reports.

CASE REPORT NO. 1

A 73-year-old white woman with intermediate stage dry AMD (Age Related Eye Disease Study [AREDS] category 3) for several years presented with baseline VA of 20/20 Snellen equivalent in each eye. Both eyes showed medium-sized drusen and were hyperopic and pseudophakic after cataract surgery. Drusen status was unchanged over an observation period of 12 months before the patient underwent PBM treatment.

Both eyes received a series of PBM treatments (ie, the recommended nine treatments with Valeda three times a week for three consecutive weeks). Seven months later, the patient received four additional treatments delivered twice a week over two consecutive weeks. Outcome measures included VA by objective refraction, OCT imaging, and automated microperimetry (Maia, CenterVue).

VA remained at 20/20 after treatment. After both sets of treatment, drusen had decreased notably in the right eye (Figure 1) and slightly in the left eye. On microperimetry, the functional macular integrity index improved in both

eyes 7 months after initial treatment, from a baseline of “abnormal” (severe deficiency) to “suspect” (mild deficiency). Concomitantly, microperimetry average threshold improved in the right eye from “suspect” to “normal” and remained in the “normal” range in the left eye after treatment. Fixation stability improved from 85% to 96% in the right eye and from 87% to 96% in the left eye. The patient reported subjective improvements in vision quality, in particular describing brighter images, better contrast, deeper color, and increased reading speed.

CASE REPORT NO. 2

A 77-year-old white woman with intermediate stage dry AMD (AREDS category 3) for several years presented with a baseline visual acuity of 20/28 Snellen equivalent in each eye. In both eyes, large drusen and a vitreous body detachment could be identified. No retinal atrophy could be identified. The eyes were hyperopic and had undergone cataract surgery.

Both eyes received the same recommended series of PBM treatments described above. VA was assessed by objective refraction, OCT images were acquired, and peripheral dark adaptation (AdaptDX, MacuLogix) was assessed before and after the PBM treatments.

One month after the end of treatment, the retinal pigment epithelial detachment, as a measure of drusen status, decreased significantly in the right eye (Figure 2) but did not change in the

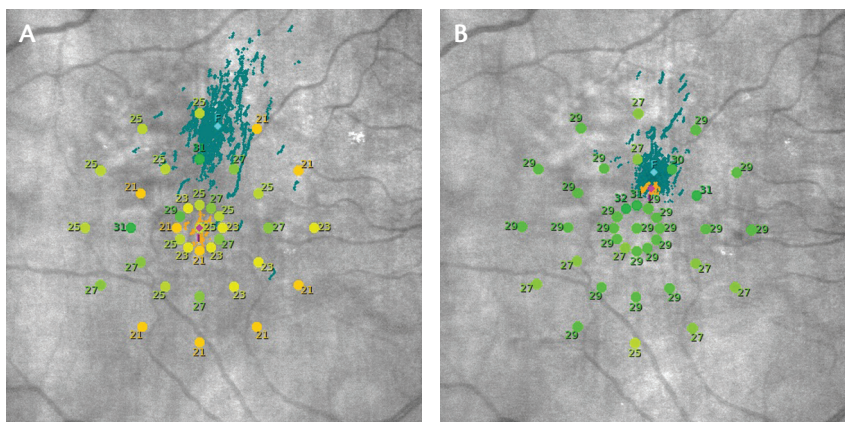


Figure 3. Color-coded results of microperimetry (response thresholds [in decibels]: green = good; yellow and orange = abnormal) and fixation position overlaid on the fundus image of the right eye, at baseline (A) and 4 months after PBM treatment (B).

left eye. Functional dark adaptation at an eccentricity of 5° did not improve, but the fixation error rate during the dark adaptation sessions improved slightly at 1 month after treatment. Although VA remained at 20/28 (0.7 logMAR), the patient reported subjective improvement in vision toward better contrast and better color after treatment.

CASE REPORT NO. 3

An 83-year-old white man with intermediate stage dry AMD (AREDS category 3) for several years presented with baseline visual acuity of 20/25 (0.8 logMAR) in both eyes with large drusen and no retinal atrophy.

The same regimen of PBM treatments with Valeda described above was administered. VA was assessed by objective refraction, OCT images were obtained, and automated microperimetry and contrast sensitivity testing (automated randomized stimuli at 6 cycles per degree) were performed before and after the PBM treatments.

Four months after the end of treatment, VA had improved from 20/25 to 20/20 in the right eye and had improved slightly in the left. On microperimetry, the functional macular integrity index improved from a baseline of “severely abnormal” to “normal,” average threshold improved from “suspect” to “normal,” and fixation stability improved from an “unstable” 53% to

“stable” 92% in the right eye (Figure 3). Similar but less prominent results were seen in the left eye. Contrast sensitivity increased by about 15% after treatment.

WHAT'S NEXT?

The benefits of PBM have been documented in one randomized clinical trial. Now, the multicenter LIGHTSITE II¹² and LIGHTSITE III¹³ clinical trials in dry AMD patients are under way in the European Union and the United States, respectively. (Valeda is investigational and not approved for use in the United States.) Additional studies are also planned or in progress to investigate the use of PBM in other ocular indications such as trauma, diabetic retinopathy and diabetic macular edema, and glaucoma.

As these additional diseases and conditions are studied, we may be able to customize light profiles and duration required for relevant treatments. Future studies will also aid in optimizing PBM treatment parameters and may expand our understanding of the mechanisms and benefit of PBM in ocular disease. ■

1. Ivandic BT, Ivandic T. Low-level laser therapy improves vision in patients with age-related macular degeneration. *Photomed Laser Surg.* 2008;26(3):241-245.
2. Merry GF, Munk MR, Dotson RS, Walker MG, Devenyi RG. Photobiomodulation reduces drusen volume and improves visual acuity and contrast-sensitivity in dry age-related macular degeneration. *Acta Ophthalmol.* 2017;95(4):e270-e277.
3. Markowitz SN, Devenyi RG, Munk MR, et al. A double-masked, randomized, sham-controlled, single-center study with photobiomodulation for

- the treatment of dry age-related macular degeneration [published online ahead of print August 9, 2019]. *Retina.*
4. Chung H, Dai T, Sharma SK, et al. The nuts and bolts of low-level laser (light) therapy. *Ann Biomed Eng.* 2012;40(2):516-533.
5. de Freitas LF, Hamblin MR. Proposed mechanisms of photobiomodulation or low-level light therapy. *IEEE J Sel Top Quantum Electron.* 2016;22(3). pii: 7000417.
6. Eells JT, Wong-Riley MT, VerHoeve J, et al. Mitochondrial signal transduction in accelerated wound and retinal healing by near-infrared light therapy. *Mitochondrion.* 2004;4(5-6):559-567.
7. Albarracín R, Eells J, Valter K. Photobiomodulation protects the retina from light-induced photoreceptor degeneration. *Invest Ophthalmol Vis Sci.* 2011;52(6):3582-3592.
8. Eells JT, Henry MM, Summerfelt P, et al. Therapeutic photobiomodulation for methanol-induced retinal toxicity. *Proc Natl Acad Sci USA.* 2003;100(6):4339-4344.
9. Tang J, Herda AA, Kern TS. Photobiomodulation in the treatment of patients with non-center-involving diabetic macular oedema. *Br J Ophthalmol.* 2014;98(8):1013-1015.
10. Ivandic BT, Ivandic T. Low-level laser therapy improves vision in a patient with retinitis pigmentosa. *Photomed Laser Surg.* 2014;32(3):181-184.
11. Ivandic BT, Ivandic T. Low-level laser therapy improves visual acuity in adolescent and adult patients with amblyopia. *Photomed Laser Surg.* 2012;30(3):167-171.
12. Study of Photobiomodulation to Treat Dry Age-Related Macular Degeneration (LIGHTSITE II). *ClinTrials.gov.* ClinicalTrials.gov Identifier: NCT03878420. Accessed May 13, 2020.
13. Study of Photobiomodulation to Treat Dry Age-Related Macular Degeneration (LIGHTSITE III). *ClinTrials.gov.* ClinicalTrials.gov Identifier: NCT04065490. Accessed May 13, 2020.

HAKAN KAYMAK, MD

- Breyer Kaymak and Klabe Eye Surgery, Macula-Retina Department, Duesseldorf, Germany
- netzhaut@augenchirurgie.clinic
- Financial disclosure: None

HARTMUT SCHWAHN, PHD

- Breyer Kaymak and Klabe Eye Surgery, Macula-Retina Department, Duesseldorf, Germany
- netzhaut@augenchirurgie.clinic
- Financial disclosure: None