


## 2 FREE CET POINTS

Approved for Optometrists ✓ Approved for DOs ✓ Approved for CLPs ✓

### CONTACT LENS PART 4

# Dealing with complex prescriptions & surgical cases

COURSE CODE: C-13550 O/D/CL



**Sophie Taylor-West BSc (Hons) MCOptom**

**Nigel Burnett Hodd BSc FCOptom Dip CLP**

Complex and high refractive errors are perhaps more pertinent cases for contact lens fitting, and therefore, practitioners should have the necessary skills to be able to fit lenses for such patients. This article discusses contact lens options for patients with high ametropia (over  $\pm 10.00$ DS) and high cylindrical prescriptions (over 3.00DC), including keratoconus, as well as more specialist surgical cases that can give rise to complex refractive errors, such as post-keratoplasty and post-refractive surgery. This will include both older, more established methods of vision correction, such as scleral and rigid gas permeable (RGP) lenses, and more modern options such as custom-lathed soft toric lenses and hybrid designs.

Fitting specialist lenses is both an art and a vocation. Practitioners either accept the challenge and go for it or shrink away and refer to another colleague. There are many patients that are bounced from one specialist to another as they have been fitted with lenses that were both expensive and unsuccessful. Your challenge, therefore, is to end their journey at your practice by fitting them successfully, following through with aftercare, and keeping them happy for the rest of their lives. The most important skills a practitioner needs when fitting lenses for complex cases are not years of experience, but enthusiasm and patience!

To fit complex contact lenses successfully requires practice and trials on

many patients; you have to make mistakes to enjoy great successes. Most of all, you must allow time. If you have a new patient with a distorted cornea, in some distress and often anxious, you can't be in a rush. At later visits you may well have to change the lenses to fine tune them or change modalities if the first ones don't work out.

Josef Dallos is perhaps the most famous UK-based fitter of the earliest specialist contact lenses and would fit people with a glass scleral lens that could usually be worn for a few hours, or in some lucky cases, all day. The lenses would be stored dry and polished with jewellers rouge every four years or so.<sup>1</sup> Whilst these lenses are now only found in antique collections, today's practitioner

is spoilt by a large range of gas permeable materials to work with, which allow the cornea to breathe better. However it is still important to remember the rules of thumb:

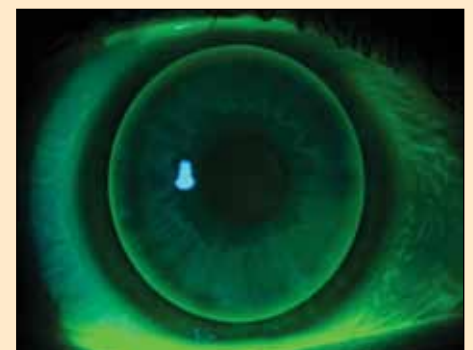- Think about sag and clinical equivalents: if you go bigger go flatter, or if you go smaller go steeper
- Think about the optics, the oxygen permeability (Dk) and transmissibility (Dk/t) and the refractive index of the materials
- Use lenses that you can trust to be made accurately – measure them yourself, in your practice and keep careful records of the specialist lenses you are fitting.

### What Are The Options?

#### Corneal RGP lenses

Corneal RGP lenses (Figure 1) are what many regard as 'normal RGPs'. The entire weight of the lens is borne by the corneal surface (and tear film). They can be manufactured from countless materials, which have varying Dk, hardness, refractive index, and wettability, all of which must be considered when ordering a lens.

The benefits of a corneal RGP lens are endless. Because they are lathe-cut on highly sophisticated, computer-controlled machinery, they can be cut to almost any shape required, and in theory to fit almost any cornea, in a reproducible manner. This includes front and back surface torics, front and back surface multifocals, aspheric designs, and even quadrant specific designs which allow the fitter to select different base curves



**Figure 1**

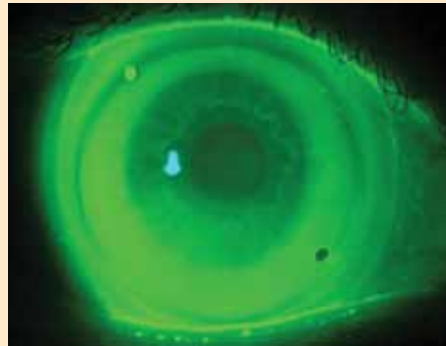
Fluorescein image of a well-fitted corneal RGP lens on a healthy eye

and peripheral curves in different quadrants of the lens. It is also possible to manufacture lenses with 'reverse curve geometry'. This simply means that unlike lenses for 'regular' corneas, reverse geometry lenses have a central base curve that is actually flatter than the peripheral curves. This means they can be made to align with oblate corneas resulting from, for example, laser in situ keratomileusis (LASIK) refractive surgery.

A successful RGP fit, on any type of cornea, will generally show the following characteristics:

- A good edge lift which facilitates tear exchange under the lens,
- allowing it to move freely on blink
- No excessively harsh bearing on any part of the cornea
- Little or no epithelial staining on removal of the lens
- A lens which will stay in the eye during blinking and excursions
- Good subjective comfort and vision.

Of course, as with all lenses, there are limitations and contraindications to corneal lenses. Some people are extremely sensitive and cannot tolerate the presence of a lens in their eye. This can be even more troubling for patients with keratoconus and post-refractive surgery, as many will not have smooth or regular corneas. Many will have a fragile corneal epithelium that can't take the constant weight of the lens. Others, particularly those with keratoconus, may be prone to giant papillary conjunctivitis (GPC) and allergies,<sup>2</sup> which can be confounded by a



**Figure 2**  
Fluorescein image of a well-fitted SoClear corneo-scleral lens on a healthy eye

small piece of plastic constantly rubbing against the papillae. Some corneas are so irregular or asymmetric that a corneal lens simply will not stay in the eye.

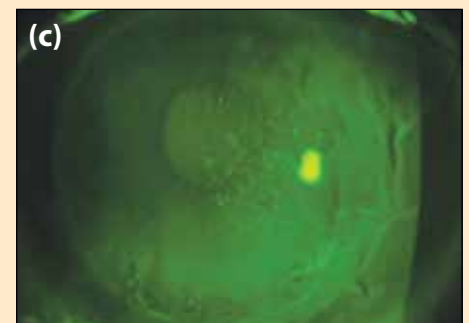
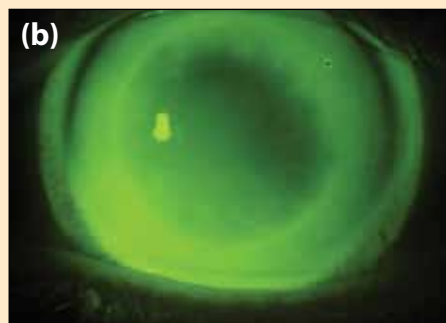
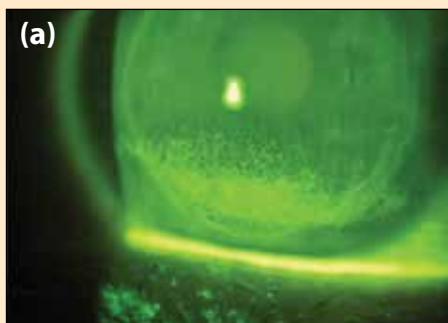
In the past, the only material available for corneal lenses was polymethyl methacrylate (PMMA), with a Dk of 0. The only way for oxygen to reach the anterior cornea was via the parts of the cornea that were not covered by the lens and from the tears flushing under the lens. Because of this, PMMA corneal lenses were traditionally very small, around 7-8mm in diameter (now known as 'micro-corneals'). This allowed the lenses to move in order to provide good tear exchange, but this was not always particularly comfortable for the patient. With the advent of gas permeable materials, corneal RGP lenses could be manufactured with larger diameters; the average diameter of RGP lenses today is around 9.5mm. Large lenses are more comfortable to wear, centralise better and

are often more stable on the eye. This has led to the development of even larger lenses, known as 'intra-limbal' lenses, with diameters of 11-12mm; an example is the Dyna IntraLimbal lens from No.7.

### Corneo-scleral lenses

Why stop at 12mm lens diameters for RGP lenses when soft lenses commonly go beyond 14mm? By flattening the peripheral curves of an RGP lens with a diameter of 14mm, so that it aligns with the scleral conjunctiva, would this not provide even better comfort and stability? As it turns out, the answer is 'yes'. Such corneo-scleral lenses (Figure 2) should share the weight of the lens between the cornea and the sclera, vaulting the limbal area entirely. If the edge of the lens is properly aligned with the sclera, the lid sensation should be practically nil, and as long as the lens doesn't move by more than 0.25mm or so on blink, it will be very comfortable. In the authors' experience, as long as the limbal area is vaulted with at least a 1-2mm band of clearance, and the periphery is not excessively tight, there should be sufficient tear exchange under the lens to prevent adhesion and tear stagnation. The lenses can be fenestrated to allow release of the negative pressure under it, allowing for easier removal.

These lenses can, of course, be used for perfectly healthy corneas, for those requiring the sharp vision of a rigid lens, with comfort levels rivalling a soft lens. This can be particularly useful for solving problems such as

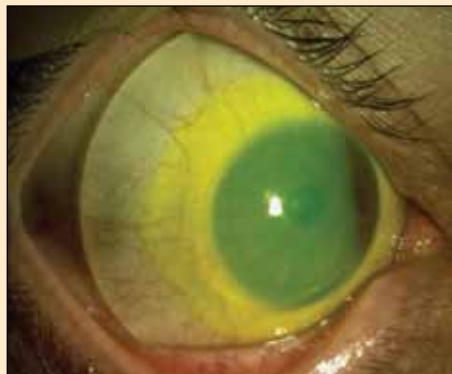

**Figure 3(a), (b) and (c)**

(a) Fluorescein staining showing significant inferior SPK on grafted cornea, prior to lens wear. Figure (b) Fluorescein fit of SoClear lens fitted to this grafted eye, showing a clearance fit that settles back to align throughout the day. Figure (c) Fluorescein staining after the patient wore this lens for two months, showing a significant improvement in the extent and depth of the SPK

## 2 FREE CET POINTS

Approved for Optometrists ✓ Approved for DOs ✓ Approved for CLPs ✓



**Figure 4**

Image of a well-fitted full scleral lens

three and nine o'clock staining, RGP intolerance, poor vision with a soft lens, a rotating soft toric, or dry soft lenses.

Another, less obvious, use of corneo-scleral lenses is as a therapeutic lens. For example, during the fitting of a post-graft eye for a patient, the authors noted that even with no lens being worn, the inferior graft was very dry and showed marked superficial punctate keratitis

(SPK) (Figure 3a). After two months of wearing a SoClear lens (Figure 3b) the SPK was significantly reduced (Figure 3c).

When fitting an irregular cornea, practitioners must to an extent abandon the "normal" way of fitting lenses, and not be so concerned with base curve. Instead it is more relevant to start thinking in terms of sagittal depth. It is not important that the curve of the lens is the same as the curve of the eye, particularly as an irregular cornea may have extremely varied topography, even within the pupil zone. It is more important that the lens rests as evenly as possible over the cornea, so that no single area receives too much pressure, as this may result in discomfort.

There are numerous corneo-scleral lens designs available, including Medlens' 'Jupiter' design, Blanchard's 'MSD' lens, and Truform's 'Digiform' range of lenses. In the UK, lens options include Jack Allen's S-LIM lens and the SoClear lens from No.7. The fitting guide for the latter lens is very comprehensive

and even a novice fitter should be able to achieve excellent results, with a little practice. Furthermore, since the lens is on average 14mm in diameter, the size is not intimidating and is actually a good place to start when considering working with larger mini-scleral and full-scleral lenses.

### Scleral lenses

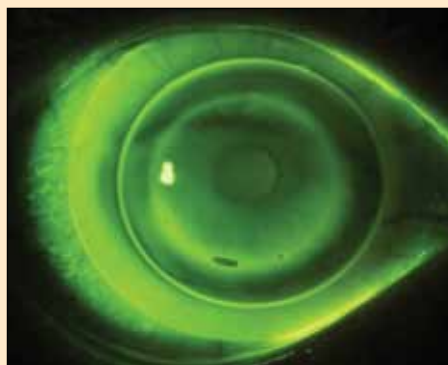
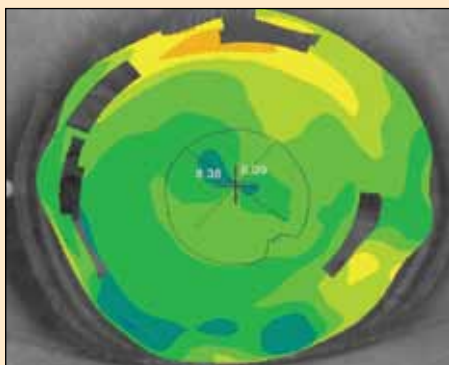
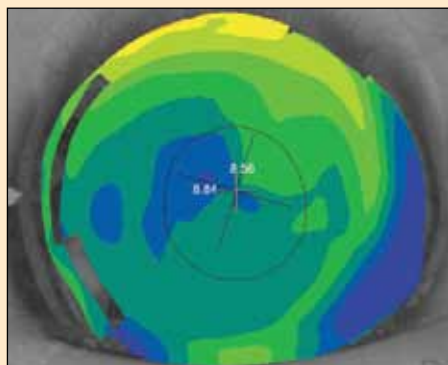
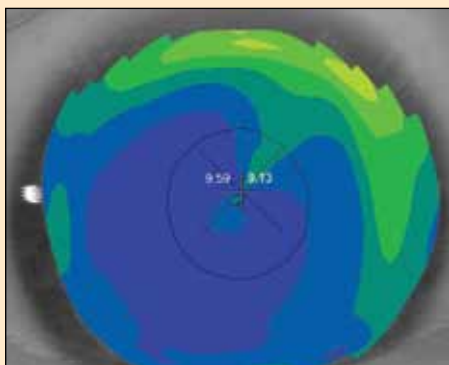
In cases where the cornea cannot take any pressure at all, for example if the epithelium is very fragile, or if the cornea is so asymmetric that the lens rests too heavily on the furthest projecting part of the cornea, it may be necessary to completely vault the cornea and limbus, so that the weight of the lens is borne fully by the sclera. These contact lenses are known as 'scleral' lenses (Figure 4).

Scleral lenses were traditionally made from PMMA, and fitting was done from fitting sets or by taking impressions. However, in more recent years it has become possible to lathe lenses from RGP materials, such as Boston XO, and these are fitted using diagnostic sets. PMMA scleral lenses for prosthetic use are produced by Cantor & Nissel and they have a specialist department run by James Courtenay. The UK company Innovative Sclerals can mould RGP sclerals but it is a very costly process. Innovative Sclerals make these lenses in a large fitting set using flat and steep series of lenses.

Mini-sclerals are generally considered to be 16-18mm in diameter, and full sclerals are 18-23mm in diameter. They are inserted by filling them completely with saline and then with the patient sitting forward with their head down, the lens is first slotted under the top lid and then tucked under the lower lid. Fitting is based on sag, and the main requirements are total vaulting over the entire cornea and limbus, and alignment with the sclera so that there is no blanching of the conjunctival blood vessels.

### Specialist soft lenses

There are makes of soft lenses that have been specially designed to mask corneal distortion. The most well-known is the Kerasoft range from UltraVision. Their hydrogel lens for corneal ectasia,



**Figure 5**

(a) Corneal topography of a post-LASIK patient with a decentred ablation zone. (b) The same eye with a +3.00 Acuvue TruEye 1-day lens. (c) The same eye with a +6.00 Acuvue TruEye 1-day lens (d) The same eye with the +6.00 Acuvue TruEye lens and a Dyna Intra Limbal lens with base curve 8.54mm piggybacked on top



**Figure 6**

Image of a hybrid contact lens design (SynergEyes)

Kerasoft 2, and the newer lathe-cut silicone hydrogel version, Kerasoft 3, can be a good choice for those with milder corneal irregularity, and those who cannot tolerate a more rigid material in the eye. UltraVision's new lens for irregular corneas is the Kerasoft IC. KeraSoft IC is designed to fit all irregular corneas, including post laser refractive surgery, Pellucid Marginal Degeneration and other complex corneal irregularities, and incorporate 'Sector Management Control' which allows the fitter to customise the periphery, similar to quadrant specific RGPs.

The main drawback to soft lenses for complex prescriptions and irregular corneas is that visual acuity (VA) is unlikely to be as clear and stable as it might be with a more rigid material. However, a longitudinal study has shown that keratoconic corneas fitted with RGPs had a slightly higher incidence of corneal scarring, so some consider fitting soft lenses as the more responsible option.<sup>3</sup>

### Piggy-Backing

The term 'piggyback' when applied to contact lenses simply means when two lenses are worn in the eye with one sitting over the other. This is typically achieved by placing a high Dk corneal RGP over a high Dk positive-powered soft carrier lens. However, it is also sometimes done the other way around.

The benefits of piggybacking are numerous. Firstly, the lens acts as a barrier and a cushion for the RGP, often making

it much more comfortable to wear. For the same reason it will protect the cornea from excessive pressure or friction effects from the RGP lens, thus reducing epithelial staining in many cases. This can be especially helpful in keratoconus cases where a central proud nebula has formed on the apex of the cone, which tends to be very sensitive but ends up bearing the central weight of the lens. The other major advantage of piggybacking an RGP over a soft lens is that the latter will help smooth out corneal irregularities, creating a much more regular shape to fit the RGP on to. The end result is an RGP lens that is more stable on the eye, centres better, is easier to fit, more comfortable for the patient and sometimes provides better vision.

It is often worth inserting lenses of different powers and performing topography with the soft lens in, to see what change of shape you have created. The authors suggest using lenses of powers +0.50DS, +3.00DS and +6.00DS, just to experiment with, to see what can be achieved. The final topography can be used as the 'new cornea' and can be used to fit the RGP lens (Figure 5).

Clearly, when using a piggyback system, it is vital to consider the Dk of the lenses you are using, as oxygen reaching the cornea will be reduced as it passes through two lenses. In the past this has meant that only monthly or two-weekly silicone hydrogel lenses were appropriate. However, since the introduction of daily disposable silicone hydrogel lenses (eg Johnson & Johnson's 1-Day Acuvue TruEye and Sauflon's Clariti one-day lenses), this has added an extra level of ease and hygiene for piggyback wearers.

The disadvantages of piggyback lens systems are: (a) Not all eyes, particularly very steep corneas such as advanced keratoconus and steep grafts, will be able to wear a soft lens without fluting at the edge. However, the authors have found that the 1-Day Acuvue TruEye lens in the 8.5mm base curve seems to fit an array of steep corneas. (b) Even with high Dk materials the oxygen reaching the cornea will be

greatly reduced compared to conventional lens wear. However, recent studies have shown that provided both the soft and hard materials have a Dk over 100, this should result in normal corneal function in most cases, provided the lenses are worn on a daily wear basis.<sup>4,5</sup>

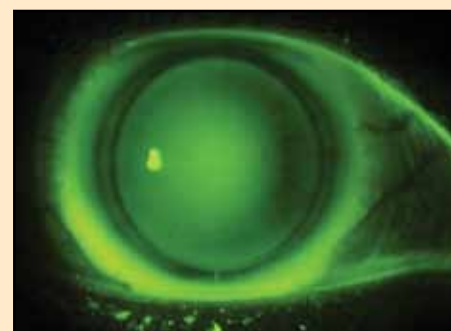
(c) The cost to the patient, both in terms of finance and time, is greater since extra time is required to insert and remove four lenses every day.

If you are unable to take topography of a cornea because it is too distorted or there is scarring, by placing a thin soft lens over the cornea you will be able to smooth out the focal irregularities and obtain an adequate topography. It might not be completely accurate in terms of curvature but it will give you an idea of the shape and severity of the condition.

The 'take-home' message here is that practitioners shouldn't be intimidated by the idea of piggybacking. Problems such as repeated vortex staining, three and nine o'clock staining, and dust under the lens, can be easily and quickly solved by placing a soft lens under the existing RGP lens.

### Hybrid lenses – soft/hard combinations

Although the idea of a soft/hard hybrid lens design (Figure 6), such as the Softperm lens, was initially developed for fitting the 'normal' healthy cornea, it was later found that greater benefit was obtained for keratoconic and irregular corneas. However, the lens became known for splitting at the soft/hard junction, and for its low Dk, which lead to hypoxic complications. In 2001, California-based

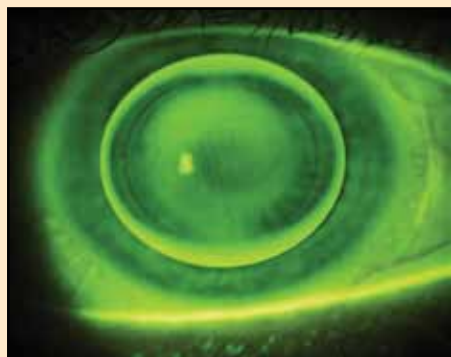


**Figure 7**

Fluorescein pattern of a SynergEyes hybrid lens fitted on a healthy ametropic cornea

## 2 FREE CET POINTS

Approved for Optometrists ✓ Approved for DOs ✓ Approved for CLPs ✓



**Figure 8**

Fluorescein pattern demonstrating a three-point-touch fit on a keratoconic eye

company SynergEyes began to develop a high Dk hybrid lens with a reliable soft/hard junction. The SynergEyes Hybrid contact lens received FDA approval and CE mark in 2005, and there are now five different designs in the range.

The SynergEyes Hybrid lens consists of an RGP centre, which is 8.4mm diameter, with a strongly bonded soft HEMA skirt giving a total lens diameter of 14.5mm. The benefit of this is that the central rigid material provides the crisp vision of an RGP, and the soft skirt provides stability, centration and comfort. They are aimed at the correction of normal ametropia, corneal astigmatism, presbyopia, keratoconus and ectasia, and post-surgical corneas such as post-graft and post-refractive surgery.

The central rigid part of the lens is designed to vault the central cornea in all cases, minimising the risk of irritation and/or scarring. The main perceived drawback to SynergEyes lenses is the low Dk of the soft skirt, which is around Dk10, and a low water content of 27%. Despite the high Dk of the RGP part (Dk100) this is still a concern to some practitioners, who eagerly await the introduction of the silicone hydrogel skirt, currently in final testing stages and due for release towards the end of 2010.

### Fitting for High Ametropia

(> ±10.00DS)

With lenses for 'normal' corneas now available in a large array of parameters, it can be difficult to decide what type of lens to fit for a patient with healthy corneas but

with a higher than average refractive error, and possibly a slightly below-average best-corrected VA. Such patients often rely on contact lenses as their main vision correction, as spectacles in such high prescriptions can be heavy, can cause marked mini/magnification effects, and produce significant aberrations. They also need their VA to be maximised. Though it might be a simpler option to fit soft monthly disposable lenses (if available in the correct parameters) or order custom-made six or 12 monthly replacement hydrogel lenses, this might not give the patient the best visual outcomes.

A first choice option that should be considered is a rigid material, which will provide the best optics for a high prescription. Traditionally this would normally be a corneal RGP lens but now other alternatives are available, which offer better comfort, more stable vision, and less chance of foreign bodies under the lens. For example, a corneo-scleral design or a hybrid lens will provide both optimal VA without constant lens movement, and also have the benefit of larger optic zones, which minimises the possibility of haloes and glare. It also abolishes the issue of edge thickness, which can be a problem in high minus-powered corneal RGP lenses.

### Fitting for High Astigmatism

(>3.00DC)

When fitting contact lenses for the correction of high degrees of astigmatism, there are numerous factors you must consider, as outlined below.

#### What does your patient do with their eyes?

Do they drive a great deal, or sit in front of a computer screen all day, for example? The first and more obvious lens choice might be a soft toric lens. Initial comfort will be good, and chair time is minimised. However, the practitioner will need to think about stabilisation methods, such as prism ballast and dynamic stabilisation, since when the cylindrical correction is high, even a very small rotation of the lens can blur the vision noticeably, and more so and for longer when compared with RGP lenses.<sup>6</sup> This can be an issue

particularly for drivers. In the authors' experience, rigid materials tend to produce more predictable, stable and sharp vision than soft toric lenses, and if your patient will tolerate such a lens, a corneal RGP with toric curves (either on the front, back, or both surfaces) can be an excellent solution. Your RGP lab will help you calculate the necessary curves if you provide them with the spectacle prescription and keratometry readings.

It is not normally recommended to fit a spherical RGP on a highly toric cornea as the subsequent rocking of the lens on the steep axis can be uncomfortable for the patient, and can cause excessive lens movement. For patients who require the vision of an RGP lens but who cannot tolerate a corneal lens, there is now a simple solution, which was not open to us two or three years ago. Provided the astigmatism is corneal, a corneo-scleral lens (see Figure 2) or a hybrid lens (Figure 7) will mask the cylinder, with the periphery of the lens resting down on the relatively spherical sclera to produce consistent, stable vision, regardless of movement on blink or lens rotation.

#### Is the astigmatism corneal, lenticular or both?

If the astigmatism is entirely or mostly corneal, this gives you the widest range of options. The toric cornea can be masked with a spherical lens by using a corneo-scleral lens fitted along the flat axis, which can provide very stable correction. Hybrid designs can also be used, to the same effect. If the astigmatism is partly accounted for by the cornea and the rest is lenticular, you may find residual cylindrical errors with such lenses. In this case your options are more limited. The best VA will probably be attained with a bi-toric RGP design, whereby the back surface is fitted to align with the corneal contour and the residual cylindrical error is worked onto the front surface of the lens. The other alternative option here is to use a soft toric lens. If your patient demands the clear vision of an RGP however, but cannot tolerate the discomfort of an RGP, don't forget that you do have the option of piggybacking.

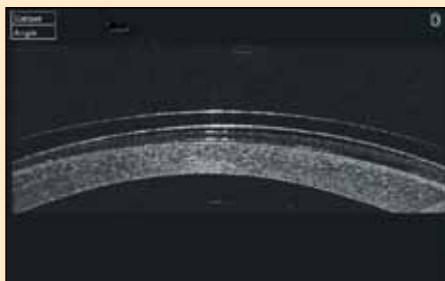
If the astigmatism is entirely or mostly lenticular, it is perhaps better to keep things simple and fit a soft toric lens. If this does not provide stable or clear enough vision, your other option is a front surface toric RGP lens, and to employ stabilisation methods such as prism ballast, truncation, or both. The technical advisors at your RGP lab will be able to advise you on this.

### Keratoconus

Until the past few years, the main lens type for keratoconus was a corneal RGP lens. There are numerous designs available, the most popular of which is the Rose K2 design (available in the UK from David Thomas – now part of Menicon Ltd.). Other designs include the Quasar K, Dyna Z Cone Plus and the new Kerakone lenses, all from No.7, and the Acuity K from Acuity Contact Lenses. These lenses have the benefits of providing (usually) optimum vision if fitted correctly, and unless lost or broken they can last many years if properly cared for, making them cost efficient for the patient. They are also easily reproducible, and designs are so advanced now that they can be modified to fit the majority of corneas, such as toric peripheries, front and back surface torics, adjustable optic zones, adjustable peripheries and even quadrant specific flattening or steepening, which is particularly useful when inferior stand-off is observed.

The typical fitting pattern for a corneal RGP lens is the classic ‘three-point-touch’ fitting, which should demonstrate a central feather touch on the apex of the cone, followed by a ring of clearance, then gentle touch-down where the weight of the lens is placed, followed by a consistent ring of edge lift (Figure 8). However, there are some disadvantages to fitting corneal RGP lenses for keratoconus, including:

- They are not suitable for contact sports
- They are prone to popping out
- They are not tolerated by everyone
- Problems with dust under the lens
- They can be easy to lose
- They aren't always suitable for very advanced or peripheral cones
- There is increased risk of corneal scarring.



**Figure 9**

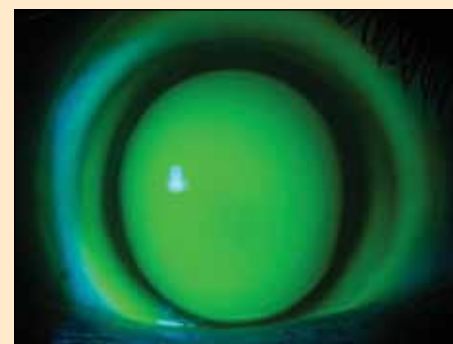
Anterior optical coherence tomography (OCT) image showing a SoClear lens piggybacked over a soft daily lens in a case of post-LASIK induced corneal ectasia

For these reasons, it is important to select the most suitable patients for these lenses, and to seek alternatives for others. For example, if your patient cannot tolerate the lens, your options are to piggyback the RGP over a soft lens or to go to the other extreme and fit a full scleral lens to completely vault the cornea. However, this will usually have a detrimental effect on VA. It is quite straightforward to place a low plus-powered daily disposable silicone hydrogel lens under an RGP lens, which will often solve many problems at once, such as dust under the lens, discomfort, corneal desiccation, three and nine o'clock staining, apical or nebular staining, and may even help the lens stay in the eye. The authors recently dealt with a particularly difficult case involving ectasia post-LASIK. The patient was very sensitive and could not tolerate corneal lenses at all, but was successfully fitted with a SoClear lens; due to the irregular corneal shape, the lens rubbed too harshly on the corneal epithelium, causing staining and discomfort and so a 1-Day Acuvue TruEye lens was placed under the SoClear lens (Figure 9), which significantly reduced the staining. The patient now achieves a clear, comfortable wearing time of 10-12 hours per day.

The Softperm lens by CIBA Vision was another useful hybrid option for lens-intolerant patients. However, the poor Dk often resulted in neovascularisation, a major problem for patients who might require future corneal grafts. SynergEyes have largely overcome this problem, with a

central Dk of 100. The lenses are also fitted so that the RGP vaults the central cornea, minimising the risk of apical staining and scarring (Figure 10). They are also very comfortable and many patients achieve a wearing time of 12 hours or more. The newest SynergEyes design for corneal ectasia, the ClearKone lens, is fitted on the principle of selecting a high enough sagittal depth to clear the cone, without the need for very steep base curves. This effectively lowers the power of the lens required and reduces the aberrations associated with very high minus-powered lenses. VA is usually close to or even better than that with a corneal RGP (according to SynergEyes' clinical data<sup>7</sup>). Hybrid lenses also have the added benefit of not displacing or falling out of the eyes, and do not gain foreign bodies under them during wear. As a result, they are a great choice for those who live or work in dusty environments or who play sports.

Corneo-scleral lenses such as the SoClear lens can also now be offered to patients with keratoconus. The authors recommend that you try to vault the cone wherever possible, to reduce the risk of staining, scarring and spectacle blur. Such lenses can also be used very effectively for patients that have also received INTACS implants in the cornea (Figure 11). When fitting SoClear lenses, it is important to be aware that the overall sag of the lens is more important than the base curve, and that the sag is controlled by the peripheral curves, not the base curve. If a diagnostic lens is inserted, which has the desired degree of corneal clearance but

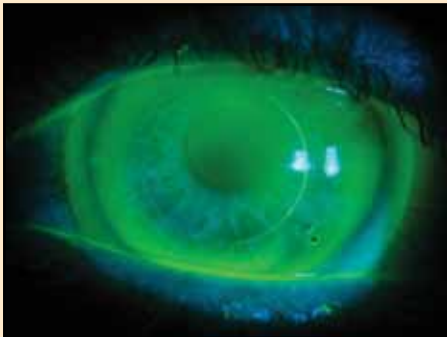

**Figure 10**

A well-fitted SynergEyes lens on a keratoconic eye, demonstrating total clearance of the ectasia

## 2 FREE CET POINTS

Approved for Optometrists ✓ Approved for DOs ✓ Approved for CLPs ✓



**Figure 11**

SoClear lens fitted on an eye with INTACS corneal implants

the periphery of the lens is too tight on the sclera, flattening the periphery will result in dropping the lens onto the cornea, which may completely alter the fit. Having said this, a stable, comfortable fit, which provides good VA, can often be attained with a little patience on your patient's part and perseverance and practice on yours.

### Post-Refractive Surgery

Despite recent advances in refractive surgical procedures, a small proportion of patients still achieve sub-optimal results for a variety of reasons including decentred ablation zones (see Figure 5a), residual ametropia, induced irregular astigmatism and occasionally anisometropia.<sup>8</sup> Even if the resultant refractive error is close to zero, these patients often complain of haloes, glare and other such aberrations, which tend to be worse at night due to pupil dilation. In such cases, contact lenses may provide the only option for visual rehabilitation and restoration of binocular vision. The challenge when fitting lenses for these corneas is due to the oblate corneal shape. Standard soft spherical or toric lenses can sometimes be used quite effectively if the cornea is still fairly regular. However, in many cases a regular soft lens will wrinkle in the centre, causing blurred and/or distorted vision. This can often be observed using a retinoscope.

Radial keratotomy (RK) in particular can produce some very extreme topography, as seen in Figure 12, which shows a highly protruding cornea with a very flat, bow-tie shaped oblate apex. Fitting Post-RK

corneas can be problematic because glare can arise from diffraction of light from the radial cuts. Lens wear, particularly of RGP lenses, causes a tear reservoir to fill the sutures, which can often reduce this phenomenon. Diurnal variations in the refraction and keratometry are also common in post-RK corneas,<sup>9,10</sup> a phenomenon which soft lenses are unable to compensate for. However, rigid lens fitting will mask this, due to the changes in the tear layer as the cornea flexes; if the cornea becomes steeper, the tear layer will consequently become more negative, and thus will cancel out the curvature change of the cornea. Another reason why soft lenses may be contraindicated in RK patients is that these patients are more likely to get new blood vessel growth along the wound sites.<sup>11</sup>

Depending on the resultant corneal topography, any of the lens types discussed in this article can be used to correct the vision in such patients. Corneal RGPs such as the Quasar aspheric design (No.7) can be fitted to the peripheral untreated cornea, which should create a good peripheral fit, but may result in significant central pooling and bubble formation, and thus sub-optimal VA. If this is the case, you may need to start thinking about reverse geometry designs like the Kerasoft IC, hybrid designs such as Synergeyes Post Surgical (PS), and limbal RGPs such as the Dyna Intralimbal. The authors have also had great success with the SoClear design, which can be manufactured with extremely flat base curves (up to around 10.80mm) but with the 'normal' periphery of the standard design; in this way the optic zone can align with the central cornea, providing superior VA with excellent comfort levels as well. Figure 13 shows a SoClear lens fitted for the cornea whose topography is shown in Figure 12. You can also create a more 'normal' cornea artificially, by fitting a soft high plus powered lens cushion on the eye and fitting a corneal RGP over the soft lens (see example in Figure 5).

Your choice of lens will depend on factors such as patient dexterity, sensitivity levels, the degree of resultant

refractive error, higher order aberrations, lens centration and cost of the lenses.

### Post-Keratoplasty

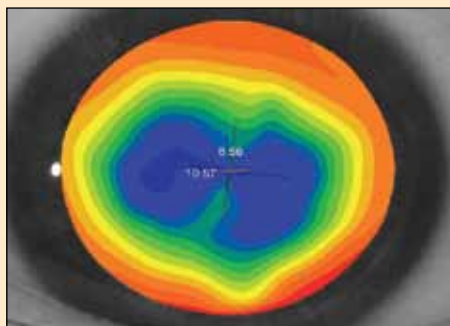
Patients who have undergone corneal graft surgery often present with significant corneal irregularity,<sup>12</sup> and fitting such corneas can be a challenging and equally rewarding undertaking. It is difficult to categorise post-keratoplasty corneas into one as the resultant topography can be so varied. Resultant graft shapes can be fairly regular to sunken, steep/protruding, or tilted. Each shape should be treated differently, as there is no 'ideal lens type' that can encompass all of these. However, the authors recommend that you keep to larger diameter lenses (11mm or greater) so as to maximise the distribution of the lens weight and to place minimal pressure on the donor tissue. Comfort and stability are also maximised with a large diameter lens. There is also often high degrees of astigmatism, which is often irregular, against the rule and asymmetric, as well as significantly more higher order aberrations than normal corneas.<sup>13,14</sup> Numerous other factors must also be borne in mind, as these will affect the suitability of the various lens options for any particular patient. Some of these are considered below.

#### Are all or some of the sutures still in place?

If all the original sutures remain, it is unwise to place undue pressure on that area and it is better to try to vault where possible. It should be borne in mind when fitting hydrogels that there is an increased risk of infection when sutures are still in place.<sup>15</sup> As all or individual sutures are removed the cornea is likely to regularise, resulting in the need for the lenses to be refitted.<sup>16</sup>

#### What is the oxygen requirement of the cornea?

When fitting a grafted cornea, it is important that the oxygen permeability of the lens material is high enough to reduce the risk of physiological complications, which could occur as a result of corneal hypoxia and consequent new vessel growth; this brings with it the natural immunological response and increases the



**Figure 12**

Corneal topography of a post-RK cornea showing a steep peripheral cornea with a flat, toric central apex

risk of graft rejection.<sup>17</sup> This is another reason why soft lenses, which need to be fairly thick to ‘smooth out’ the corneal irregularities, should be considered a last resort, in the authors’ opinion.

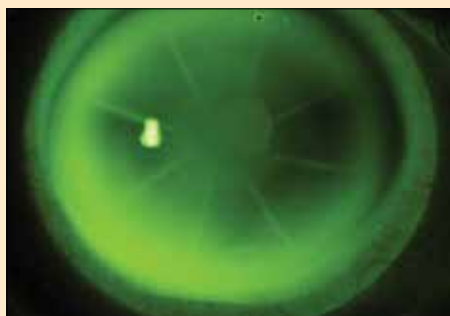
**Is there a high degree of astigmatism, and is the astigmatism regular or irregular?**

It has been shown that around 20% of corneal grafts have 5.00DC or more of astigmatism, and of these, around 18% have irregular astigmatism.<sup>17</sup> Soft toric lenses or spectacles may be able to correct regular astigmatism but cannot fully correct irregular astigmatism. A rigid material will be required in these cases to optimise VA.

**The graft location, diameter and relationship with host cornea**

**Sunken/Flat graft**

When the central corneal curvature is flatter than the peripheral host corneal curvature or the donor tissue is depressed below the host tissue, this is described as a ‘sunken graft’. A soft daily disposable



**Figure 13**

Fluorescein image of a SoClear lens fitted for the cornea shown in Figure 12

contact lens can often help even out the harsh host/graft junction interface of a very sunken graft, before placing an RGP on top, which is important to minimise the risk of graft rejection. Reverse geometry lenses may be necessary to fit such corneas. The Synergeyes PS lens is a hybrid design with a reverse curve RGP centre, which can be very useful in fitting oblate corneas, provided that the donor graft diameter is less than the RGP centre, ie smaller than 8.4mm. Soft hydrogel or silicone hydrogel lenses such as Kerasoft IC can be manufactured with reverse curves also, and scleral lenses are another alternative for this graft type. It is also possible to manufacture SoClear lenses with reverse curve type designs, and, provided there is sufficient tear exchange, very good VA and comfort can be attained with these lenses.

**Steep/Proud graft**

When the central cornea is significantly steeper than the host cornea, this can be thought of as a steep or proud graft. Occasionally the graft itself will be quite flat, but elevated above the host cornea, in which case it is known as a ‘plateau’ shaped graft. Topography is sometimes difficult to take, and assessment of the corneal shape can be easier by looking at the profile of the cornea, or displacement of the lower lid on down gaze. These corneas tend to have a very high sagittal depth. These factors make it very difficult to fit lenses in the preferred way ie landing the lens on the host cornea and vaulting the donor corneas as much as possible. The authors suggest either a corneo-scleral, mini-scleral or full scleral design should be used. In some cases you may be successful with a limbal lens, but aim to place as little bearing on the host/donor junction as possible.

**Tilted graft**

Where one side of the graft is significantly more elevated than the other, a steep-to-flat contour otherwise known as a ‘tilted’ graft is produced. High degrees of irregular astigmatism typically accompany this graft, which requires correction with a rigid lens; however fitting contact lenses can

be particularly difficult because corneal lenses tend to centre over the steepest part of the cornea. Certain modifications can be made to RGP lenses to improve centration, such as incorporating prism ballast if the steeper meridian is located superiorly, or making the lens larger and flatter, or with a negative carrier, to encourage lid-hitch in the case of inferior steepening.<sup>17</sup> Placing a soft lens under the RGP can reduce any corneal insult to the part of the cornea that receives the heaviest touch from the rigid lens. If it is not possible to centre the lens over the optical axis, your only option may be to vault the entire cornea with the aid of a corneo-, mini- or full scleral lens. This may involve a fair bit of extra chair time, but can achieve excellent results on these otherwise very tricky corneas.

It has been shown that central corneal sensitivity in post-keratoplasty eyes is greatly reduced,<sup>18</sup> so your patient will not necessarily notice the discomfort caused by an ill-fitting lens, corneal abrasions or other forms of corneal compromise. For this reason you must take extra care when fitting contact lenses for grafted corneas, and be vigilant in the detection and elimination of insult to the donor tissue.

**Conclusion**

The plethora of contact lens modalities and designs now available to practitioners means that there is no reason not to provide patients with the best possible means of vision correction, in terms of VA, comfort and corneal physiology. Although mastering these techniques and designs may take time and patience, we owe it to ourselves and our patients to have a go.

**About the Authors**

Sophie Taylor-West is an optometrist at the private practice of Nigel Burnett Hodd in Devonshire Street, London. She is also an optometric consultant to No. 7 contact lens laboratory. Mr Burnett Hodd is currently Honorary Pioneers Day organiser for the BCLA and Secretary of the International Society of Contact Lens Specialists.

**References**

See [www.optometry.co.uk/references](http://www.optometry.co.uk/references)



## 2 FREE CET POINTS

Approved for Optometrists ✓ Approved for DOs ✓ Approved for CLPs ✓

### Module questions

### Course code- C-13550 O/D/CL

**1. Which of the following is the LEAST important consideration when fitting complex contact lenses?**

- (a) The sagittal depth of the lens
- (b) Oxygen permeability and transmissibility of the lens
- (c) Refractive index of the lens
- (d) Disposability of the lens

**2. Which sub-set of patients is particularly susceptible to giant papillary conjunctivitis and allergies?**

- (a) Those with keratoconus
- (b) Those with high astigmatism
- (c) Those who wear soft contact lenses
- (d) Those who had unsuccessful LASIK surgery

**3. Which type of contact lens showed a surprising therapeutic effect on a graft patient?**

- (a) A small diameter corneal RGP lens
- (b) A SynergEyes Hybrid lens
- (c) A corneal-scleral lens
- (d) A piggyback soft lens over an RGP lens

**4. If you have difficulty obtaining a good corneal topography, which of the following is the most appropriate course of action?**

- (a) Insert an average fitting contact lens on and see how it fits
- (b) Insert a thin soft lens to mask the irregularities for the topographer
- (c) Get the patient to look down and observe the lower lid displacement for an estimate of the curvature
- (d) Anaesthetise the eye, take an impression, make a cast and measure using callipers

**5. What is the basic fitting feature of the SynergEyes Hybrid lens for patients with keratoconus?**

- (a) They are fitted to press on the cone to stop progression of the disease
- (b) They are fitted on the three-point touch principle like an RGP lens
- (c) They are fitted flat to encourage movement and tear exchange
- (d) They are fitted to completely vault the cornea and put the bearing surfaces on the limbal-conjunctiva

**6. Which instrument is recommended to best observe the optical effects of a soft lens wrinkling in the centre?**

- (a) A slit-lamp
- (b) A pen torch
- (c) An ophthalmoscope
- (d) A retinoscope

**7. A "plateau" shaped corneal graft describes when:**

- (a) The graft is quite flat but elevated above the host cornea
- (b) The central cornea is significantly steeper than the host cornea
- (c) The central cornea curvature is flatter than the peripheral host corneal curvature
- (d) One side of the graft is more elevated than the other

**8. Studies have shown that central corneal sensitivity in post-keratoplasty eyes is:**

- (a) Increased
- (b) Unchanged
- (c) Reduced
- (d) Greatly reduced

**9. What is the main drawback of fitting soft lenses to irregular corneas?**

- (a) Lenses are very expensive
- (b) Lenses are difficult to insert and remove
- (c) Visual acuity is unlikely to be as clear and stable as with a rigid lens design
- (d) Lenses cannot be worn all day

**10. Which of the following statements about piggyback systems is FALSE?**

- (a) The power of the soft cushion lens can be altered to change the fitting characteristics of the RGP
- (b) A +3.00D change in power of the soft cushion lens changes the power of the optical system by around +3.00D
- (c) Putting a hard lens under a soft lens is also considered a piggyback system
- (d) On very steep corneas it may not be possible to get a soft lens cushion to fit the eye without edge fluting or displacement

**11. When fitting post-keratoplasty patients, what is the best way to avoid corneal hypoxia?**

- (a) Use a high DK/t contact lens arrangement
- (b) Avoid applying pressure to sutured areas
- (c) Fit the lenses to encourage good oxygen transmission and tear flow
- (d) All of the above

**12. Which of the following is an advantage to fitting corneal RGP lenses?**

- (a) They can be used for all occasions even in contact sports
- (b) Dust under the lenses does not cause any discomfort
- (c) The visual acuity is often very good
- (d) They are well tolerated in the eye by most patients

**PLEASE NOTE** There is only one correct answer. All CET is now FREE. Enter online at [www.optometry.co.uk](http://www.optometry.co.uk) by midnight on May 26 2010. You will be unable to take this exam after this date – answers to the exam will be published online ten days after the closing date.



Keith Tempary FBDO CL FBCLA, one of a team of 15 Practice Academy consultants

## Practice ACADEMY

BRINGING THE ACADEMY FOR EYECARE EXCELLENCE™ TO YOUR PRACTICE.

Contact your CIBA VISION Business Development Manager and find out how your practice can benefit from high quality, in-store training delivered by a Practice Academy consultant



"The cost of this type of training would ordinarily be prohibitive, but with the help of CIBA VISION I can maximise the potential of my contact lens business."

Darren Madoo MCOptom  
Observatory, The Opticians